

## Case Report

# Colorectal Perforation Following Retroperitoneal Arterial Reconstruction in a Patient after Pelvic Irradiation

Yasuhiro Fujii, Hideya Mitsui, and Shunji Sano

**Abstract:** A 53-year-old woman who had a history of radical hysterectomy, pelvic radiation therapy, and chemotherapy against cervical cancer underwent retroperitoneal left ilio-femoral bypass for occlusion of the left external iliac artery. Because cryptogenic mild-to-moderate abdominal pain appeared after the surgery, laparotomy was performed postoperative day 18. Upon detection of rectal perforation, colostomy and ileostomy were performed. In the case of a patient with a history of pelvic radiation therapy and laparotomy, we should attend to the increased risk of rectal necrosis, and carefully consider the use of early laparotomy for diagnosis and treatment. ( J Jpn Coll Angiol, 2006, 46: 481–484 )

**Key words:** arteriosclerosis obliterans, radiation, intestinal perforation

## Introduction

Colorectal perforation is a rare complication in pelvic vascular surgery, especially when performed via retroperitoneal approach.<sup>1</sup> Although not enough attention have been paid for the complication, a patient with a history of pelvic radiation therapy (RT) or laparotomy appears to be at the increased risk of colorectal perforation. In this report, we present a case of colorectal perforation after performing left common ilio-femoral bypass via a retroperitoneal approach due to obstruction of left external iliac artery with a history of pelvic RT and laparotomy.

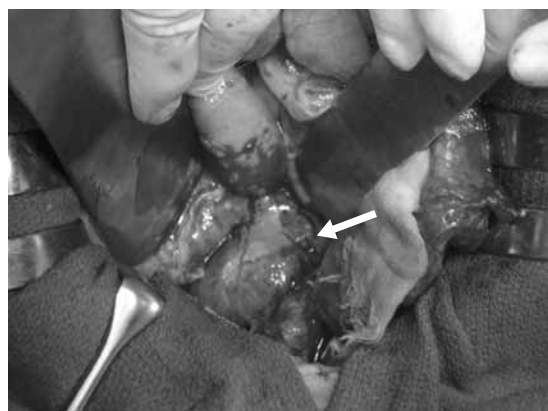
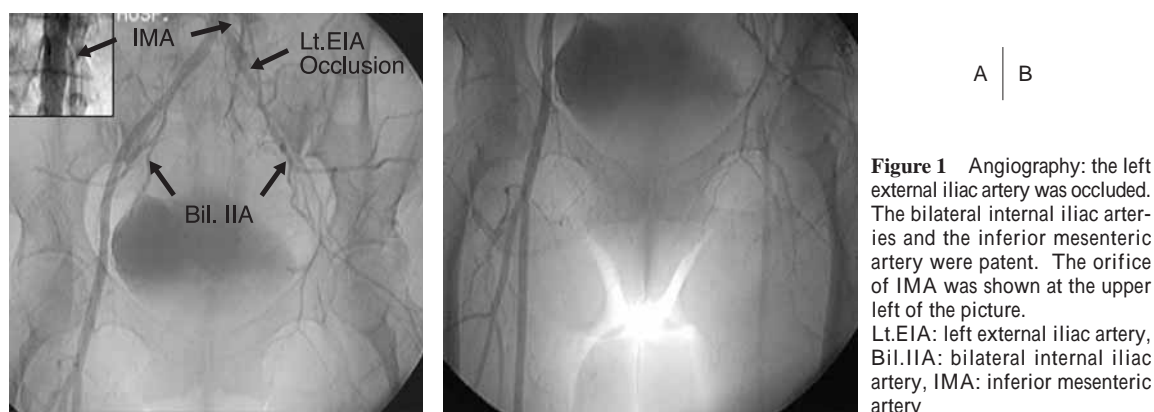
## Case

A 53-year-old woman with a history of cervical cancer, stage IB squamous cell carcinoma visited our hospital complaining of intermittent claudication (100 meters) of her left calf. Five years previously she underwent radical hysterectomy, linac 50Gy RT, and chemotherapy (Nedaplatin 20mg/m<sup>2</sup>/week for 7 weeks, tegafur/uracil 450mg/day for 2

years). With watery diarrhea, acute radiation bowel injury had been suspected after the RT. The pulses of her left dorsalis pedis artery and posterior tibial artery were not palpable, and the left and right ankle-brachial index (ABI) were 0.34 and 1.06 respectively. Additional physical examination, electrocardiogram, chest X-ray, abdominal X-ray, and laboratory data showed no abnormalities. The angiography revealed obstruction of the left external iliac artery without significant stenosis of the distal artery. The blood supply of pelvic organs seemed sufficient because the bilateral internal iliac arteries and the inferior mesenteric artery were patent (**Fig. 1**). The left ilio-femoral bypass using a Dacron graft (Gelsoft® ø8mm, Vascutek Terumo) was performed under generalized heparinization using a retroperitoneal approach on right decubitus position using a left abdominal transverse incision and left inguinal longitudinal incision. Since there was no adhesion in her retroperitoneal space, no strong traction was required to achieve an excellent visual field and we succeeded in exposing the iliac arteries. The peritoneum was not injured, making the operation complete without any incidents. Total intraoperative bleeding was approximately 200 ml. After surgery, her left ABI improved to 1.40. The patient

Department of Cardiovascular Surgery, Dentistry and Pharmaceutical Science, Okayama University Graduate School of Medicine, Okayama, Japan

Received December 9, 2005      Accepted July 14, 2006



**Figure 2** The proximal portion of the rectum was perforated (arrow).

complained of soft-to-moderate abdominal pain and tenderness without a guarding or rebound phenomenon just after surgery, and the pain worsened. She presented with a high fever, nausea, and appetite loss, while having no signs of constipation or gastromegaly. There were no signs of infection on her operative wound. Some examinations were carried out to determine the cause of her symptoms. Chest X-ray in the standing position revealed no free flowing air under the diaphragm. There were no findings indicating the presence of an ileus, abscess or mass in the abdominal cavity on abdominal X-ray and abdominal CT scan. Gallium scintigraphy revealed an accumulation all over the colon, but there was no localized accumulation indicative of an abscess or a tumor. But as the white blood cell count (WBC) and C-

reactive protein (CRP) remarkably increased (WBC. 20,700/mm<sup>3</sup>, CRP 21.5 mg/dl), we suspected peritonitis, and an exploratory laparotomy was performed on postoperative day 18. An abdominal midline incision was made, and severe adhesion was found upon search of the patient's abdominal cavity. The proximal portion of the rectum wall was very thin and a perforation was detected (**Fig. 2**). The severe adhesion and infection of surrounding tissue inhibited the closure of the rectum stump that was covered with the mesentery of the distal ileum. With the abdominal cavity well-irrigated, transverse colostomy and ileostomy were carried out, and five drains were placed in the abdominal cavity. The left common ilio-femoral bypass graft was located in the retroperitoneal space, so it could not be confirmed during surgery. There was pus discharge from these drains, and we did irrigate from the drains. As discharge gradually decreased, all drains were removed by day 42 after the second operation. After discharged, the patient was admitted to another hospital to do her rehabilitation at 60 days after the second operation. At present, she can walk normally without any ischemic symptoms.

## Discussion

In this case, the patient had no risk factors for arteriosclerosis obliterans (ASO) except for RT 5 years previously. Arterial occlusion was strictly localized, and the patient's arterial wall was very smooth, excluding the portion of the occlusion. ASO due to radiation injury of the arterial wall is noted to yield the following: a relatively large artery will

suffer from radiation injury, localized arterial sclerosis and occlusion.<sup>2,3</sup> The TransAtlantic Inter-Society Consensus (TASC) classification indicates this case was type D, for which TASC recommends surgical re-vascularization. On the basis of a history of radical hysterectomy and pelvic RT for cervical cancer, we suspected severe adhesions of the abdominal cavity thereby selecting a retroperitoneal approach.

In this patient, radiation injury seems responsible for the thin and fragile rectal wall. Moreover, radical hysterectomy may have caused severe adhesion existed around the rectum. Thus, even gentle tractions during surgery may have injured the rectum. The most probable cause, we believed, was colonic perforation. Some other causes such as thromboembolism, injuries of the arteries which feed the sigmoid colon and rectum and steal syndrome after re-vascularization were ruled out because the lesion was very localized, not segmented.

Post-RT diarrhea the patient had points to her intestinal radiation injury. Lanciano et al. compiled data from a number of RT facilities, reporting that major complications, defined as those necessitating hospitalization, are seen in 9.8 % of patients with cervical cancer following RT. Of these complications, the majority was noted in the large and small bowel (61%).<sup>4</sup> Eifel et al. reported that the incidence of sigmoid perforation in a group of patients with stage IB disease is 0.6% at 20 years.<sup>5</sup> Radiation injury to the gastrointestinal tract occurs as a biphasic process. First, there is mucosal cell injury, which manifests itself acutely with symptoms consistent with enterocolitis, usually occurring at 4 and 5 weeks of treatment. The second, and often less frequently recognized, is injury to vascular and connective tissue. Such late features manifest as small and large bowel obstruction secondary to vasculitis, diffuse collagen deposits, and fibrosis in submucosa and subserosa leading ultimately to strictures. This may become evident a few months to 30 years or more after RT.<sup>6</sup> A number of factors are linked to the development of RT complications. Most notable are the dose of radiation and dose per fraction, radiation duration, and the volume of tissue irradiated.<sup>7</sup> In addition, patients with a history of abdominal surgery, pelvic inflammatory disease, or diverticulosis are at greater risk of developing radiation-induced complications. Such conditions may create adhe-

sions to the uterus: loops of the bowel are restricted from moving during radiation treatment.<sup>8</sup> Because this patient had both a history of pelvic RT and hysterectomy, she was thought to be a high risk patient for colorectal perforation.

The question arises as to how we can prevent this type of complication. It was important to take notice of the patient's history of pelvic RT and radiation enteritis. This time, we gave priority to the preservation of anatomical blood flow since the patient was young. If there is, however, some evidence of chronic radiation injury of the gastrointestinal tract, such as a past history of acute radiation enteritis, chronic or frequent abdominal pain, diarrhea, constipation, occult blood, or indications of an inflamed change in pelvic CT scan, we may have to select an extra-anatomical bypass. Questions clearly remain regarding selection of an operative procedure for patients who have undergone pelvic RT.

In order to achieve early detection, we should keep in mind that patients who have undergone pelvic RT do not show classical symptoms of acute abdomen, even when they suffer from colon or rectal perforation. Ramirez et al. reported that nearly half (41%) of the patients had no evidence of acute peritonitis on physical examination, and only 30% of patients were diagnosed with colorectal perforations at an early stage.<sup>9</sup>

We believe that a transverse colostomy and ileostomy were the proper procedures because of the high mortality and morbidity for patients undergoing surgery for radiation-induced bowel injuries.<sup>10</sup> Diverting the flow of stool and, if possible, excising a perforated section of the bowel increases efficacy of treatment for perforation of radiation-injured colon.

## Conclusion

Pelvic RT may pose a risk of developing colorectal perforation in vascular surgery for the pelvis. Despite difficulty in diagnosing colorectal perforation, we were able to treat this patient by drainage, an ileostomy, and a transversocolostomy.

## References

- 1) Darling C 3rd, Shah DM, Chang BB et al: Current status of the use of retroperitoneal approach for reconstructions of the aorta and its branches. *Ann Surg*, 1996, **224**: 501–508.
- 2) Benson EP: Radiation injury to large arteries. 3. Further

- examples with prolonged asymptomatic intervals. *Radiology*, 1973, **106**: 195–197.
- 3) Moutardier V, Christophe M, Lelong B et al: Iliac atherosclerotic occlusive disease complicating radiation therapy for cervix cancer: a case series. *Gynecol Oncol*, 2002, **84**: 456–459.
- 4) Lanciano RM, Martz K, Montana GS et al: Influence of age, prior abdominal surgery, fraction size, and dose on complications after radiation therapy for squamous cell cancer of the uterine cervix. A patterns of care study. *Cancer*, 1992, **69**: 2124–2130.
- 5) Eifel PJ, Levenback C, Wharton JT et al: Time course and incidence of late complications in patients treated with radiation therapy for FIGO stage IB carcinoma of the uterine cervix. *Int J Radiat Oncol Biol Phys*, 1995, **32**: 1289–1300.
- 6) Deitel M, Degani C, Alexandar MA: Major gastrointestinal problems after radiotherapy: management and nutritional considerations. *Int Surg*, 1977, **62**: 334–337.
- 7) Marks G, Mohiuddin M: The surgical management of the radiation-injured intestine. *Surg Clin North Am*, 1983, **63**: 81–96.
- 8) Unal A, Hamberger AD, Seski JC et al: An analysis of the severe complications of irradiation of carcinoma of the uterine cervix: treatment with intracavitary radium and parametrial irradiation. *Int J Radiat Oncol Biol Phys*, 1981, **7**: 999–1004.
- 9) Ramirez PT, Levenback C, Burke TW et al: Sigmoid perforation following radiation therapy in patients with cervical cancer. *Gynecol Oncol*, 2001, **82**: 150–155.
- 10) Dirksen PK, Matolo NM, Trelford JD: Complications following operation in the previously irradiated abdominopelvic cavity. *Am Surg*, 1977, **43**: 234–241.